

## **GB 21**

### **Location**

In the upper fibres of trapezius at the highest point of the shoulder; midway between C7 and the acromion

### **Anatomy**

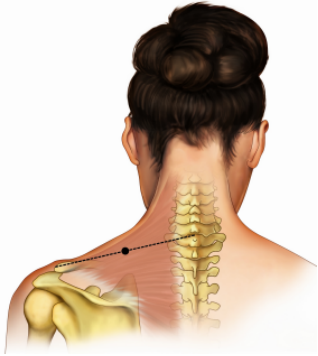
*Muscle:* The upper portion of the trapezius

*Nerve:* Accessory nerve

*Blood vessel:* Branch of the transverse cervical artery

### **Technique**

Insert needle 0.5 – 1.0 cun perpendicular to the surface; need to avoid injury to the lung



May not be exactly as shown in the 2009 course syllabi